

Heterogeneous ribonucleoprotein K is a marker of oral leukoplakia and correlates with poor prognosis of squamous cell carcinoma

Ajay Matta^{1,2}, Satyendra Chandra Tripathi³, Leroi V. DeSouza^{1,2}, Jörg Grigull⁴, Jatinder Kaur³, Shyam Singh Chauhan³, Anurag Srivastava⁵, Alok Thakar⁶, Nootan Kumar Shukla⁷, Ritu Duggal⁸, Siddhartha DattaGupta⁹, Ranju Ralhan^{1,2,10,11,12,13*} and K.W. Michael Siu^{1,2}

¹Department of Chemistry, York University, Toronto, Ontario, Canada

²Centre for Research in Mass Spectrometry, York University, Toronto, Ontario, Canada

³Department of Biochemistry, All India Institute of Medical Sciences, New Delhi, India

⁴Department of Mathematics and Statistics, York University, Toronto, Ontario, Canada

⁵Department of Surgical Disciplines, All India Institute of Medical Sciences, New Delhi, India

⁶Department of Otorhinolaryngology, All India Institute of Medical Sciences, New Delhi, India

⁷Department of Surgery, Dr. B. R. A. Institute Rotary Cancer Hospital, All India Institute of Medical Sciences, New Delhi, India

⁸Department of Dental Surgery, All India Institute of Medical Sciences, New Delhi, India

⁹Department of Pathology, All India Institute of Medical Sciences, New Delhi, India

¹⁰Joseph and Mildred Sonshine Family Centre for Head and Neck Diseases, Mount Sinai Hospital, Toronto, Ontario, Canada

¹¹Department of Otolaryngology – Head and Neck Surgery, Mount Sinai Hospital, Toronto, Ontario, Canada

¹²Department of Pathology and Laboratory Medicine, Mount Sinai Hospital, Toronto, Ontario, Canada

¹³Department of Otolaryngology – Head and Neck Surgery, University of Toronto, Toronto, Ontario, Canada

Oral leukoplakia is a heterogeneous lesion with risk of cancer development; there are no biomarkers to predict its potential of malignant transformation. Tissue proteomic analysis of oral leukoplakia using iTRAQ labeling liquid chromatography–mass spectrometry showed overexpression of heterogeneous ribonucleoprotein K (hnRNP K), a transformation-related RNA-binding protein, in leukoplakia in comparison with normal tissue. Herein, we investigated the clinical significance of hnRNP K in identification of oral leukoplakic lesions in early stages and as a prognostic marker in head-and-neck/oral squamous cell carcinomas (HNSCCs). Immunohistochemical analysis of hnRNP K was performed in 100 HNSCCs, 199 leukoplakias and 55 nonmalignant tissues and correlated with clinicopathologic parameters and disease prognosis over 6 years for HNSCCs. hnRNP K nuclear expression increased from normal tissues to leukoplakia, and frank malignancy ($p < 0.001$). Cytoplasmic hnRNP K increased significantly from leukoplakia to HNSCCs ($p < 0.001$) and was associated with poor prognosis of HNSCCs ($p = 0.011$) by Kaplan–Meier analysis. The most important finding of our follow-up study is that cytoplasmic hnRNP K is an independent predictor of disease recurrence in HNSCC patients. In conclusion, nuclear hnRNP K may serve as a potential marker for early diagnosis, whereas its cytoplasmic accumulation can help to identify a subgroup of HNSCC patients with poor prognosis, suggesting its putative utility in clinical management of HNSCC.

© 2009 UICC

Key words: hnRNP K; oral leukoplakia; squamous cell carcinoma; head-and-neck cancer; prognosis

Head-and-neck/oral squamous cell carcinoma (HNSCC) is the sixth most common cancer in the United States and the fourth most prevalent cancer in men worldwide.¹ Oral squamous cell carcinoma (OSCC), the most common form of HNSCC, is often preceded by clinically well-defined lesions, such as leukoplakia, which is causally linked with chronic exposure of the oral mucosa to carcinogens/growth promoters in tobacco and alcohol; leukoplakias with dysplasia are, herein, defined as oral premalignant lesions (OPLs).^{2–4} The presence of dysplastic areas in the oral epithelium is associated with a likely progression to cancer; however, it is not an accurate predictor of cancer risk.^{5,6} Identification of biomarkers that can differentiate the high-risk lesions from more benign lesions is of critical importance for early intervention of high-risk cases. Rapid advances in treatment modalities and improvements in the early detection of oral cancer have not significantly impacted the overall survival rates of cancer patients (about 50% at 5 years). Major thrust has been laid on genomics-

and proteomics-based identification of cancer markers that can predict the clinical outcome in HNSCC patients, after treatment of primary tumors. These novel biomarkers will hopefully transform clinical practice by including cancer screening and diagnosis based on molecular markers as a complement to histopathology.

Heterogeneous ribonucleoprotein K (hnRNP K) or transformation upregulated nuclear protein is a 464-residue protein, belonging to the RNA-binding protein family, with 3 KH domains that mediate DNA/RNA binding and overlapping transactivation and nuclear shuttling domains.^{7,8} The hnRNP family of proteins have diverse cellular functions in the regulation of chromatin remodeling, transcription, mRNA shuttling, RNA splicing, RNA editing and translation and may have potential roles in tumorigenesis.^{9–17} hnRNP K binds to DNA in a sequence-specific manner to the CT elements located in the promoter region of human proto-oncogene *c-myc*, enhancing transcription to promote cell proliferation, survival and migration.¹² In response to DNA damage, both p53 and hnRNP K are recruited to the promoters of p53-responsive genes in a mutually dependent manner for transcription of cell-cycle checkpoint genes.¹³ Expression of hnRNP K is increased in several human malignancies: chronic myelogenous leukemia and solid tumors, including cancers of the esophagus, lung, nasopharynx and colorectum.^{14–18} hnRNP K is involved in the initiation of cell spreading and cell migration—a process essential for tumor cell invasion and cancer metastasis, thereby making it a potential target for metastasis therapy.^{19,20} The involvement of hnRNP K in tumorigenesis is also reflected by its regulation by growth factors²¹ and its overexpression in SV40-transformed cells.²² Recently, increased hnRNP K transcripts have been reported in oral cancer.²³ Thus, most studies have focused on hnRNP K

Abbreviations: DICE, differentiation-control element; hnRNP K, heterogeneous ribonucleoprotein K; HNSCC, head-and-neck/oral squamous cell carcinoma; LOX, 15-lipoxygenase; NPV, negative predictive value; OPLs, oral premalignant lesions; OSCC, oral squamous cell carcinoma; PPV, positive predictive value; ROC, receiver operating characteristic.

RR and KWMS are senior authors in this study.

The first two authors contributed equally to this study.

*Correspondence to: Centre for Research in Mass Spectrometry, Department of Chemistry, York University, 4700 Keele Street, Toronto, Ontario, Canada M3J 1P3. Fax: +(416)736-5936.

E-mail: ralhanr@yorku.ca or Rralhan@mtsinai.on.ca

Received 16 January 2009; Accepted after revision 26 March 2009

DOI 10.1002/ijc.24517

Published online 22 April 2009 in Wiley InterScience (www.interscience.wiley.com).

expression in cancers, but its role in early premalignant stages remains unexplored.

Recently, we have used isobaric mass tags, iTRAQ and multidimensional liquid chromatography/tandem mass spectrometry (LC-MS/MS) for comparing the protein expression patterns of human oral leukoplakias with dysplasia and nonmalignant tissues. hnRNP K was discovered, identified and verified to be overexpressed in oral dysplasias and emerged among the panel of 3 potential biomarkers for OPLs.²⁴ Interestingly, hnRNP K was also found to be overexpressed in a subset of HNSCCs in another independent study by our group, but it did not satisfy our criteria of a potential cancer marker by iTRAQ analysis (as the iTRAQ ratios in complex biological samples are often compressed²⁵) and, hence, was not included in this report.²⁶ Nevertheless, in view of the role of hnRNP K as a transformation-related protein, its overexpression in oral leukoplakia and HNSCCs is an important finding and in-depth studies are warranted to determine its significance in early stages of development of oral leukoplakia, before malignant transformation.

Herein, we hypothesized that altered hnRNP K expression may occur in early stages of development of HNSCCs and impact disease progression. To verify this hypothesis, we have determined the clinical significance of hnRNP K expression in different stages of development and progression of head-and-neck/oral cancer by immunohistochemistry using a monoclonal antibody against hnRNP K, and correlated the findings with clinicopathologic parameters. A unique feature of our study is the relevance of hnRNP K as a biomarker for leukoplakia with dysplasia or without dysplasia and poor prognosis of head-and-neck cancer that has been assessed by correlating its expression with disease outcome in follow-up studies of HNSCC patients.

Material and methods

Patients, clinicopathologic data collection, tumor and biopsy specimens

The Institutional Human Ethics Committee of the All India Institute of Medical Sciences (AIIMS), New Delhi, India, approved this study before its commencement. Tissue specimens were obtained from diagnostic or therapeutic procedures from 199 patients with oral leukoplakia (115 cases with no histologic evidence of dysplasia, 84 cases with dysplasia: mild dysplasia 68 cases; moderate dysplasia 12 cases and severe dysplasia 4 cases) attending the Outpatient Clinic of the Departments of Surgical Disciplines and Otolaryngology, AIIMS, and from 100 HNSCC patients undergoing curative cancer surgery during the period 2002–2007, after obtaining patient consents. The age of patients with oral leukoplakia ranged from 16 to 75 years, median 42 years; males 159; females 40. The age of HNSCC patients ranged from 25 to 85 years, median 53 years; males 75; females 25. Wherever possible, nonmalignant tissues ($n = 30$) were taken from a site distant from the surgically resected HNSCC patients. Nonmalignant normal oral tissues ($n = 25$) were also collected from the patients attending the Outpatient Department of Dental Surgery for tooth extraction. Taken together, these 55 nonmalignant oral tissues with histologic evidence of normal epithelium constituted the normal group. After excision, tissues were immediately snap-frozen in liquid nitrogen and stored at -80°C in the Research Tissue Bank till further use; 1 part of the tissue was collected in 10% formalin and embedded in paraffin for histopathologic and immunohistochemical analyses.

The histopathologic grading of epithelial dysplasia was based on evaluation of architectural and cytological changes following the WHO classification and the recent reviews.^{4,5} For each case, the pathologist recorded the grade and details of the criteria on which the decision was based. Leukoplakic lesions were classified into 2 groups: (i) lesions with no dysplasia and (ii) lesions with dysplasia (mild, moderate or severe). Histologically confirmed oral normal epithelia, leukoplakia with evidence of no dysplasia or with dysplasia, and HNSCCs as revealed by H&E staining

were used for immunohistochemistry.²⁶ Patient demographic, clinical and pathologic data were recorded in a predesigned form as described previously.²⁷ The information documented included clinical TNM staging (tumor, node, metastasis based on the Union International Center le Cancer TNM classification of malignant tumors 1998), site of the lesion, histopathologic differentiation, age, gender and tobacco consumption habits.

Follow-up study

Seventy-seven HNSCC patients who underwent treatment from 2002 to 2007 were also investigated and evaluated in the head-and-neck cancer follow-up clinic at regular time intervals. Survival status of the HNSCC patients was verified and updated from the records of the Tumor Registry, Institute Rotary Cancer Hospital, AIIMS, as of May 2008. HNSCC patients were monitored for a maximum period of 76 months (range 1–76 months; mean 24 months and median 12 months). As per the hospital protocol, HNSCC patients with T₁ and T₂ tumors were treated with radical radiotherapy or surgery alone, whereas the majority of patients with T₃ and T₄ diseases were treated by radical surgery followed by postoperative radical radiotherapy as described by us.²⁷ The patients were revisited clinically on a regular basis and the time to recurrence was recorded. If a patient died, the survival time was censored at the time of death; the medical history, clinical examination and radiological evaluation were used to determine whether the death had resulted from recurrent cancer (relapsing patients) or from any other causes. Disease-free survivors were defined as patients free from clinical and radiological evidence of local, regional, or distant relapse at the time of the last follow-up. Loco-regional relapse/death was observed in 47 of 77 (61%) patients monitored during the follow-up. Thirty patients who did not show recurrence were alive until the end of the follow-up period. Only disease-free survival was evaluated in the current study, because the number of deaths due to disease progression did not allow a reliable statistical analysis. Disease-free survival was expressed as the number of months from the date of surgery to loco-regional relapse.

Immunohistochemistry

Paraffin-embedded sections (5 μm) of human oral nonmalignant tissues ($n = 55$), leukoplakic lesions [with no dysplasia ($n = 115$) or with dysplasia ($n = 84$)] and HNSCCs ($n = 100$) were collected on gelatin-coated slides. Immunohistochemistry conditions were optimized and evaluated by 3 of us (S.C.T., A.M., S.D.G.). In brief, the sections were deparaffinized in xylene, hydrated in gradient alcohol and pretreated in a microwave oven for 10 min in Tris-EDTA buffer (0.01 M, pH = 9) for antigen retrieval. The sections were incubated with hydrogen peroxide (0.3% v/v) in methanol for 30 min to quench the endogenous peroxidase activity, followed by blocking with 1% bovine serum albumin (BSA) to preclude nonspecific binding. Thereafter, the slides were incubated with mouse monoclonal anti-hnRNP K antibody (1 $\mu\text{g}/\text{ml}$, ab23644, Abcam, Cambridge, MA) for 16 hr at 4°C . The primary antibody was detected using the streptavidin–biotin complex with the Dako LSAB plus kit (Dako CYTOMATION, Glostrup, Denmark) and diaminobenzidine as the chromogen.²⁴ All procedures were performed at room temperature unless otherwise specified. Slides were washed with Tris-buffered saline (TBS, 0.1 M, pH = 7.4), 3–5 times after every step. Finally, the sections were counterstained with Mayer's hematoxylin and mounted with D.P.X mountant. In the negative control tissue sections, the primary antibody was replaced by isotype-specific nonimmune mouse IgG. A section from colorectal cancer tissue was used as a positive control in each batch of immunohistochemistry. The sections were evaluated by light microscopic examination.

Evaluation of immunohistochemical staining

Each slide was evaluated for hnRNP K immunoreactivity using a scoring system for both staining intensity and percentage of pos-

itive epithelial cells as described earlier by us.²⁴ Immunopositive staining was evaluated in randomly selected 5 areas of the tissue section. For hnRNP K protein expression, sections were scored as positive if epithelial cells showed immunopositivity in the nucleus/cytoplasm when observed independently by 3 of us (S.C.T., A.M., S.D.G.), who were blinded to the clinical outcome (the slides were coded and the scorers did not have prior knowledge of the local tumor burden, lymphonodular spread and grading of the tissue samples). The tissue sections were scored based on the % of immunostained cells as: 0–10% = 0; 10–30% = 1; 30–50% = 2; 50–70% = 3 and 70–100% = 4. Sections were also scored on the basis of staining intensity as negative = 0; mild = 1; moderate = 2; intense = 3.¹⁸ Finally, a total score was obtained by adding the score of percentage positivity and intensity. In cases where both nuclear and cytoplasmic immunoreactivity was observed, the nuclear and cytoplasmic staining was scored independently. The scoring by all 3 observers (S.C.T., A.M., S.D.G.) was discrepant in about 5% cases and a consensus on the final result was reached by re-evaluation of these slides and discussion.

Statistical analyses

The immunohistochemical data were subjected to statistical analyses using the SPSS 10.0 software (Chicago). Sensitivity and specificity were calculated and quantified using receiver operating characteristic (ROC) analyses. The predictive value (PV) describes the proportion of correctly classified cases. Based on sensitivity and specificity values for hnRNP K, a cutoff ≥ 5 was defined as positive criterion for hnRNP K immunopositivity for statistical analyses. The relationships between hnRNP K protein expression and clinicopathologic parameters were tested using chi-square and Fischer's exact test. Two-sided *p* values were calculated and *p* < 0.05 was considered to be significant.

Systematic and rigorous assessment of positive and negative predictive values (PPV and NPV) for prognostic biomarkers is a relatively recent development in biostatistical theory and is described in detail in references.^{28,29} For the follow-up study of HNOSCC cases, let *T* denote the failure time, *i.e.*, the first time recurrence is diagnosed after surgical removal of the tumor. For these data, the positive and negative predictive values as functions of time are defined as follows:

$$PPV_{\text{nuclear}}(t) = \text{Prob}(T \leq t \text{ and recurrence} | \text{hnRNP K (nuclear)} \geq 5);$$

$$NPV_{\text{nuclear}}(t) = \text{Prob}(T > t \\ \text{or no recurrence} | \text{hnRNP K (nuclear)} < 5); 0 \leq t \leq 76,$$

and, analogously, for cytoplasmic hnRNP K. These probabilities are estimated from the observed accumulated incidences over the respective time periods. The correlation of hnRNP K staining with patient survival was evaluated using life tables constructed from survival data with Kaplan–Meier plots.

Cell culture and confocal laser scan microscopy (CLSM)

Human oral squamous carcinoma cell line, HSC2 (JCRB0622), was obtained from Health Science Research Resources Bank, Japan. SCC4, Tu167 and MDA1986 were a kind gift from UT MD Anderson Cancer Center, Houston, Texas, USA. Cells were grown in monolayer cultures in Dulbecco's modified eagle medium (DMEM/DMEM-F12) (Sigma, St. Louis, MO) supplemented with 10% fetal bovine serum (Sigma), 1 mM L-glutamine, 1× sodium pyruvate, 1× vitamins, 1 mM MEM, 100 µg/ml streptomycin and 100 U/ml penicillin in a humidified incubator (5% carbon dioxide, 95% air) at 37°C. To study the subcellular localization of hnRNP K protein, immunofluorescence (IF) using CLSM was determined in SCC4 cells. For IF, 5×10^4 cells were plated on cover slips and grown for 24 hr. Thereafter, cells were washed with phosphate-buffered saline (PBS, 0.01 M, pH = 7.2) and fixed in acetone:methanol mixture (1:1) for 20 min. Cells were washed and perme-

abilized with 0.2% Tween in PBS followed by blocking with 2% BSA for 1 hr. These cells were then incubated with mouse monoclonal anti-hnRNP K antibody (Abcam) at 4°C O/N. Expression of hnRNP K protein was determined by FITC-labeled secondary antibody (DAKO Cytomation, Denmark) as described earlier³⁰.

Reverse transcription-PCR

Head-and-neck cancer cells (SCC4, HSC2, Tu167 and MDA1986) and representative frozen tissue specimens of histologically confirmed oral normal tissues, leukoplakia and HNOSCCs were used for extraction of total RNA using the TRI reagent (Sigma, MO) as previously described.³¹ First-strand cDNA was synthesized using 2 µg RNA with oligo dT as the primer with MMLV reverse transcriptase. PCR was performed using hnRNP K specific primers forward-(5'-AGCAGAGCTCG GAATCTTCCTT-3') and reverse-(5'-ATCAGCACTGAAAC CAACCAT GCC-3'). Twenty microliters of each PCR product was used for electrophoresis on a 1.5% agarose gel stained with ethidium bromide. The gel was visualized with UV light and photographed.²⁴

Immunoblot analysis of hnRNP K in oral tissues

Whole cell lysates were prepared from SCC4 cells, oral non-malignant, leukoplakia and HNOSCC tissues by homogenization in lysis buffer containing 50 mM Tris-HCl (pH = 7.5), 150 mM NaCl, 10 mM MgCl₂, 1 mM ethylenediamine tetraacetate (EDTA, pH = 8.0), 1% Nonidet P-40, 100 mM sodium fluoride, 1 mM phenylmethylsulfonamide and 2 µl/ml protease inhibitor cocktail (Sigma) as previously described.²⁴ Protein concentration was determined using the Bradford reagent (Sigma) and equal amounts of proteins (50 µg/lane) were resolved on 10% sodium dodecyl sulfate-polyacrylamide gel. The proteins were then electro-transferred onto polyvinylidene difluoride membrane. After blocking with 5% nonfat powdered milk in Tris-buffered saline (TBS, 0.1 M, pH = 7.2), blots were incubated with anti-hnRNP K monoclonal antibody (1 µg/ml, Abcam) at 4°C overnight. Protein abundance of β-actin (rabbit polyclonal antibody, Cell Signaling Technology, MA) served as a control for protein loading in each lane. Membranes were incubated with HRP-conjugated goat anti-mouse secondary antibody, (DAKO Cytomation, Glostrup, Denmark), diluted at an appropriate dilution in 1% BSA, for 2 hr at room temperature. After each step, blots were washed 3 times with Tween (0.1%) Tris-buffer saline. Protein bands were detected by the enhanced chemiluminescence method (ECL, Santa Cruz Biotechnology, CA) on XO-MAT film.

Results

Immunohistochemical analysis of hnRNP K expression in oral lesions

To determine the clinical significance of hnRNP K protein in head-and-neck tumorigenesis, its expression was analyzed in different stages of HNOSCC development by immunohistochemistry using a specific monoclonal antibody. Of the 55 histologically normal tissues analyzed, 51 cases (93%) showed faint or no detectable hnRNP K immunostaining in the nucleus/cytoplasm of the epithelial cells (Fig. 1a); 4 cases showed nuclear immunopositivity (Table I, Fig. 1b). Chi square trend analysis showed significant increase in nuclear hnRNP K staining in different stages of head-and-neck/oral tumorigenesis (normal, leukoplakia and HNOSCCs; Table I, *p*_{trend} < 0.001). Of the 199 leukoplakias analyzed, 141 cases (71%) showed significant increase in nuclear hnRNP K immunostaining in comparison with the normal tissues [*p* < 0.001, Odds ratio (OR) = 30.9, 95% CI = 10.7–89.7, Table I]. Oral leukoplakia is a clinical terminology and histologically these lesions were classified into leukoplakia with no dysplasia or with dysplasia. Of the 199 leukoplakias, 115 cases showed no histologic evidence of dysplasia; 78/115 (68%) cases showed significant increase in nuclear hnRNP K immunoreactivity (IHC scoring range 0–7, median score 5) in comparison with the normal tissues

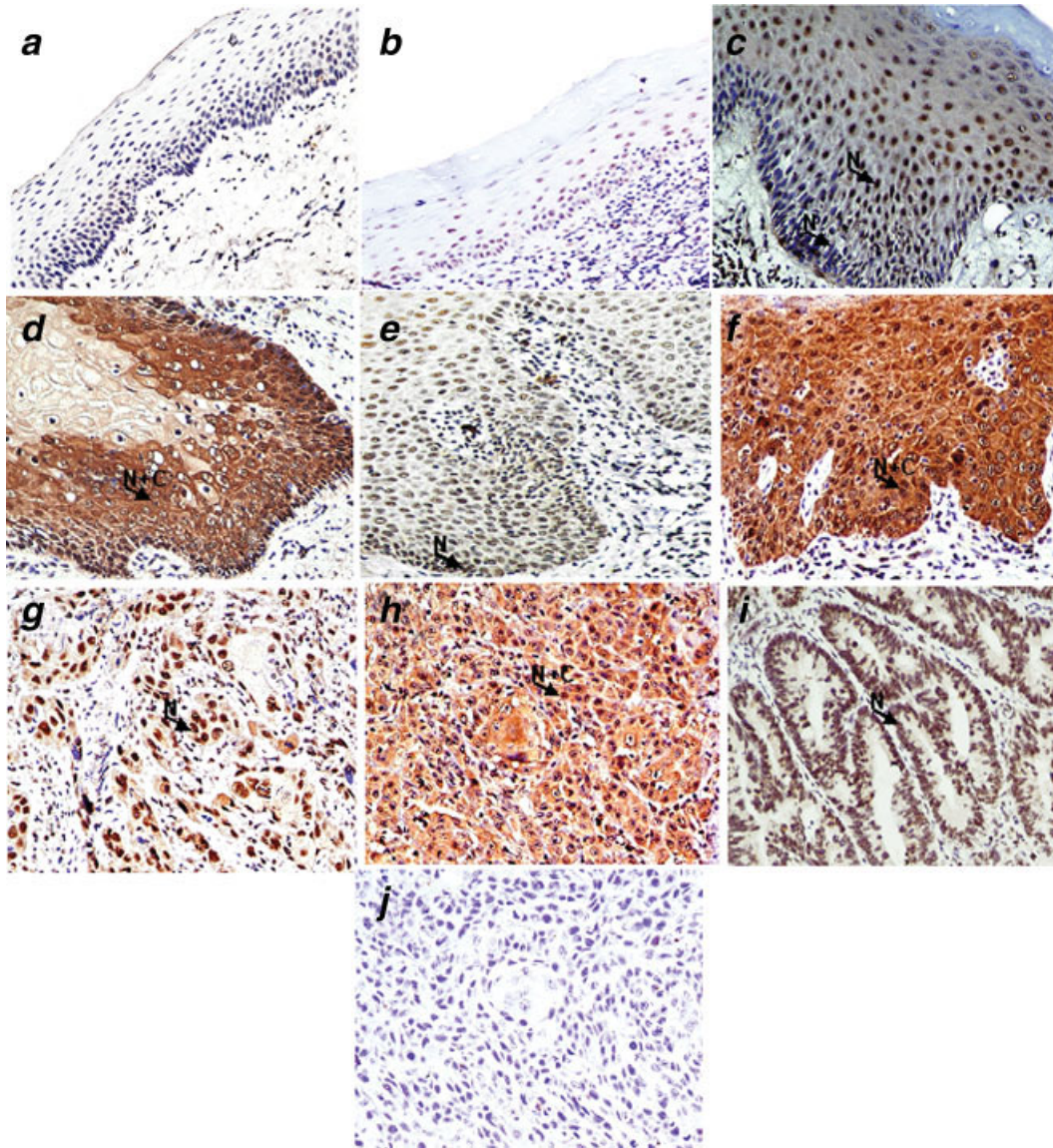


FIGURE 1 – Immunohistochemical analysis of hnRNP K in head-and-neck/oral tissues. Paraffin-embedded sections of histologically normal mucosa, leukoplakia with no evidence of dysplasia or with dysplasia and HNSCCs were stained using anti-hnRNP K monoclonal antibody as described in the Methods section. (a) Normal oral mucosa showing no hnRNP K immunostaining; (b) normal oral mucosa showing moderate nuclear hnRNP K immunostaining; (c) leukoplakic lesion with no dysplasia showing intense nuclear and faint cytoplasmic hnRNP K immunostaining in basal, para-basal and supra-basal layers of mucosa; (d) leukoplakic lesion with no dysplasia showing increased nuclear and cytoplasmic hnRNP K immunostaining in basal and para-basal layers of mucosa; (e) dysplasia depicting intense nuclear hnRNP K immunostaining in epithelial cells; (f) dysplasia depicting intense nuclear and cytoplasmic hnRNP K immunostaining in epithelial cells; (g) HNSCC section illustrating only nuclear hnRNP K immunostaining in the tumor cells; (h) HNSCC section showing both cytoplasmic and nuclear staining in tumor cells; (i) colorectal cancer tissues showing intense nuclear hnRNP K immunostaining; (j) HNSCC section used as a negative control, showing no hnRNP K immunostaining in tumor cells. Arrows show nuclear localization (N) of hnRNP K in panels b, c, e, g and i; nuclear and cytoplasmic localization (N+C) in panels d, f and h (a–j, original magnification $\times 400$).

(IHC scoring range 0–6, median score 2) ($p < 0.001$, OR = 26.8, 95% CI = 9.1–79.9, Table I and Fig. 1c). Importantly, progressive increase in nuclear expression of hnRNP K was observed in 75% dysplasias (63 of 84 cases, Fig. 1e), with IHC score ranging from 2 to 7, median score 6, in comparison with normal tissues ($p < 0.001$, OR = 38.2, 95% CI = 11.7–113.1). It is noteworthy that 26 of 199 leukoplakia cases showed cytoplasmic localization of hnRNP K, in addition to its nuclear expression, as shown in Figs. 1d and 1f, respectively. The majority of HNSCCs (78%) showed nuclear localization of hnRNP K in tumor cells (Fig. 1g), with IHC score ranging from 3 to 7, median score 6. In addition to nuclear staining, intense hnRNP K staining was also observed

in the cytoplasm of tumors cells in 38 of 100 HNSCCs analyzed (Fig. 1h) with IHC score distribution: < 5 in 62 cases; IHC score = 5 in 12 cases; 6 in 21 cases; and 7 in 5 cases. The clinicopathologic parameters of HNSCCs patients and their correlations with nuclear/cytoplasmic expression of hnRNP K are shown in Table I. Increased cytoplasmic hnRNP K staining was significantly associated with histologic grade of HNSCCs ($p_{\text{trend}} = 0.001$). The positive control (colorectal cancer) showed nuclear expression of hnRNP K protein (Fig. 1i), whereas no immunostaining was observed in tissue sections used as negative controls where the primary antibody was replaced by isotype specific IgG (Fig. 1j).

TABLE I – ANALYSIS OF hnRNP K PROTEIN EXPRESSION IN ORAL LESIONS AND CORRELATION WITH CLINICOPATHOLOGIC PARAMETERS

Clinicopathologic features	Total cases	Nuclear Positivity, N (%)	<i>p</i>	OR (95% CI)	Cytoplasmic Positivity, N (%)	<i>p</i>	OR (95% CI)
Normal	55	4 (7)			—		
Leukoplakia	199	141 (71)	<0.001 ¹	30.9 (10.7–89.7)	26 (13)	<0.001 ²	4.3 (2.2–7.2)
No dysplasia	115	78 (68)	<0.001 ³	26.8 (9.1–79.9)	18 (16)	<0.001 ⁴	4.3 (1.8–6.3)
Dysplasia	84	63 (75)	<0.001 ⁵	38.2 (11.7–113.1)	8 (10)	<0.001 ⁶	5.8 (2.5–13.4)
Mild dysplasia	68	50 (74)	0.77	—	7 (10)	0.784	—
Moderate dysplasia	12	10 (83)			1 (8)		
Severe dysplasia	4	3 (75)			—		
HNOSCC	100	78 (78)	<0.001 ⁷	45.2 (14.7–138.8)	38 ⁸ (38)		
Differentiation						0.001	
WDSCC	45	33 (73)	0.31	—	9 (20)		—
MDSCC	49	39 (79)			24 (49)		
PDSCC	6	6 (100)			5 (83)		
Tumor stage						0.19	
T ₁	4	4 (100)	0.42	—	3 (75)		—
T ₂	35	28 (80)			15 (43)		
T ₃	25	17 (68)			6 (24)		
T ₄	36	29 (81)			14 (39)		
Nodal status						0.52	
N ₀	33	24 (73)	0.37	—	14 (42)		—
N _{1–4}	67	54 (81)			24 (36)		
Habits						0.41	
Nonconsumer	22	19 (86)	0.28	—	10 (45)		—
Tobacco consumer	78	59 (75)			28 (36)		

Nuclear staining: ¹Normal vs. leukoplakia; ³Normal vs. leukoplakia with no evidence of dysplasia; ⁵Normal vs. dysplasia; ⁷Normal vs. HNOSCCs; N/L/HNOSCCs: $p_{\text{trend}} < 0.001$.

Cytoplasmic staining: ²Leukoplakia vs. HNOSCCs; ⁴Leukoplakia with no evidence of dysplasia vs. HNOSCCs; ⁶Dysplasia vs. HNOSCCs; N/L/HNOSCCs: $p_{\text{trend}} < 0.001$. ⁸HNOSCCs showed both nuclear and cytoplasmic hnRNP K staining.

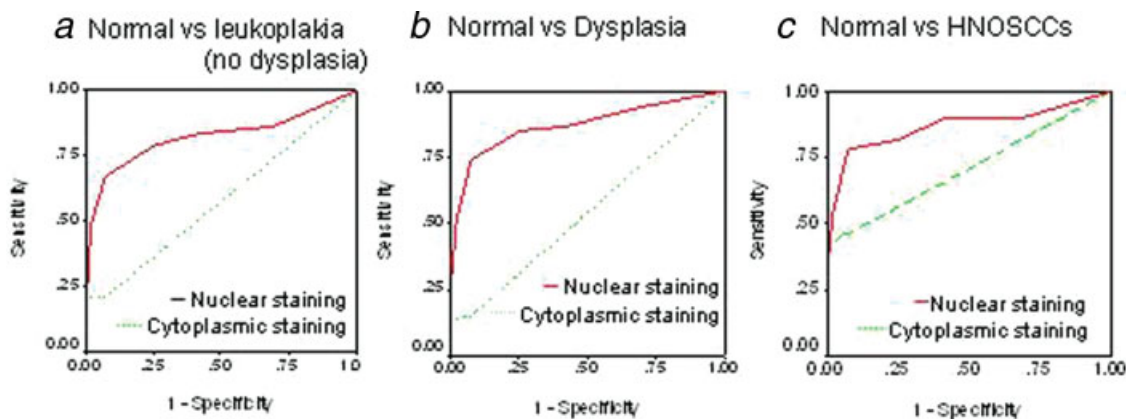


FIGURE 2 – Receiver operating characteristic curves of hnRNP K (nuclear/cytoplasmic) in (a) normal vs. leukoplakia with no evidence of dysplasia; (b) normal vs. dysplasia; (c) normal vs. HNOSCCs. Bold line shows ROC analysis for nuclear hnRNP K. Dashed line shows ROC analysis for cytoplasmic hnRNP K. [Color figure can be viewed in the online issue, which is available at www.interscience.wiley.com.]

Evaluation of hnRNP K as potential biomarker for diagnosis and/or prognosis

ROC curve analysis was used to determine the potential of hnRNP K as a biomarker to distinguish leukoplakia and HNOSCCs from normal oral epithelium. The values for area-under-the-curve (AUC) were 0.822, 0.872 and 0.869 for leukoplakia without dysplasia (Fig. 2a), with dysplasia (Fig. 2b) and cancer (Fig. 2c), respectively, with respect to normal oral tissues based on the total score for nuclear immunostaining (Table II). The positive predictive values (PPV) were 92.7, 92.3 and 92.3%, respectively, for nuclear immunostaining in the 3 groups. Similarly, ROC analysis was used to determine AUC and PPV for cytoplasmic hnRNP K staining in all these 3 groups as shown in Table II and Figures 2a–2c.

hnRNP K expression as a predictor of disease progression and prognosis

Significantly, the follow-up data of 77 HNOSCC cases for 76 months were used to assess the prognostic value of hnRNP K for

predicting cancer recurrence in HNOSCC patients after completion of primary treatment. Both positive predictive and negative predictive values of the prognostic test are of paramount importance in this context, with the former to correctly identify cases that need early intervention, and with the latter to gauge, in the most accurate way, where such intervention with its monumental personal impacts can and should be avoided. Figure 3 shows the estimated PPVs and NPVs for nuclear and cytoplasmic hnRNP K expression as prognostic biomarkers for cancer recurrence in HNOSCC patients (Figs. 3a and 3b). Based on our data, the additional prognostic value, which hnRNP K, in either its nuclear or cytoplasmic expression, provides for predicting (PPV) or excluding (NPV) cancer recurrence in HNOSCC patients is PPV_{nuc} (76 months)/ PPV_{overall} (76 months) = 68.9/61.0; PPV_{cyto} (76 months)/ PPV_{overall} (76 months) = 81.3/61.0; NPV_{nuc} (76 months)/ NPV_{overall} (76 months) = 68.9/39.0; and NPV_{cyto} (76 months)/ NPV_{overall} (76 months) = 53.3/39.0. Based on these analyses, the most significant improvement over clinicopathologic criteria that cytoplasmic hnRNP K appears to offer as a marker is in predicting

TABLE II – BIOMARKER ANALYSIS OF hnRNP K (NUCLEAR/CYTOPLASMIC) IN ORAL LESIONS

hnRNP K	Sensitivity	Specificity	PPV	AUC
Nuclear staining				
Normal vs. leukoplakia (no dysplasia)	67.0	92.7	94.8	0.822
Normal vs. leukoplakia (dysplasia)	74.1	92.3	93.7	0.872
Normal vs. OSCCs	78.0	92.3	95.1	0.869
Cytoplasmic staining				
Normal vs. leukoplakia (no dysplasia)	15.3	100	100	0.577
Normal vs. leukoplakia (dysplasia)	8.3	100	100	0.543
Normal vs. OSCCs	38.1	100	100	0.709

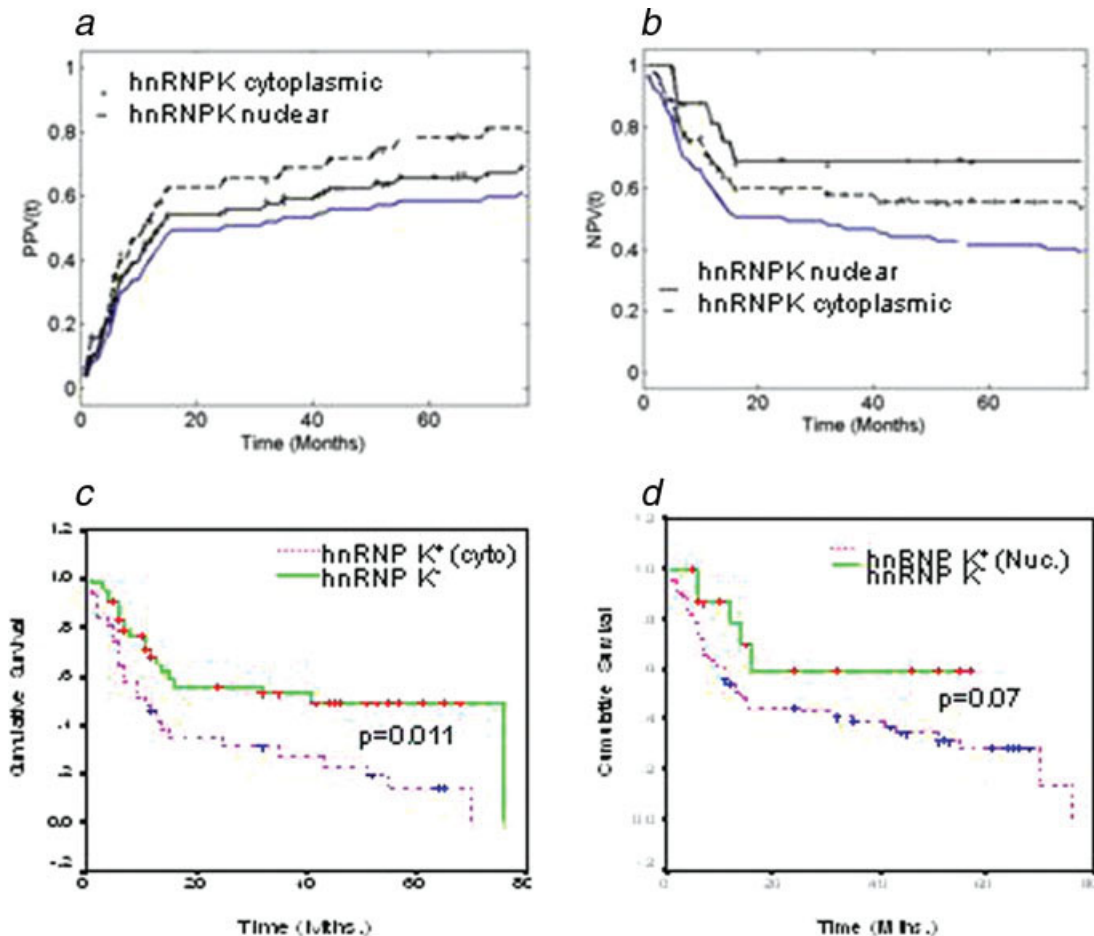


FIGURE 3 – Evaluation of hnRNP K expression (nuclear/cytoplasmic) as a prognostic marker of HNSCCs. Panels *a* and *b* show the estimated positive predictive value (PPV) and negative predictive value (NPV) for nuclear/cytoplasmic hnRNP K expression as prognostic markers for recurrence in HNSCC patients, respectively. Kaplan–Meier estimation of cumulative proportion of disease-free survival: (*c*) Median time for disease-free survival (DFS; no recurrence/metastasis) in HNSCC patients showing cytoplasmic immunostaining of hnRNP K was 11 months, whereas in patients showing no/faint hnRNP K-immunostaining in cytoplasm median DFS was 41 months ($p = 0.011$). (*d*) In patients showing increased nuclear hnRNP K expression the median DFS was 14 months compared with HNSCCs that showed mild or moderate nuclear immunostaining (median DFS = 57 months, $p = 0.07$). [Color figure can be viewed in the online issue, which is available at www.interscience.wiley.com.]

prognosis of HNSCCs. Although PPVs and NPVs quantify the estimated predictive power of the marker, the strength of the statistical association of hnRNP K expression with poor prognosis was assessed by Kaplan–Meier survival analysis.

Kaplan–Meier survival analysis showed significantly reduced disease-free survival ($p = 0.011$; median survival 11 months) in HNSCC patients harboring increased cytoplasmic expression of hnRNP K, compared with median disease-free survival of 41 months in the patients showing no/faint cytoplasmic hnRNP K immunostaining (Fig. 3c). Similarly, reduced disease-free survival of 14 months was observed in HNSCC patients showing intense nuclear expression of hnRNP K, compared with patients who did

not show increased nuclear hnRNP K (median survival of 57 months), although this could not reach a statistically significant value of $p \leq 0.05$ (Fig. 3d). Logistic regression analysis (multivariate) was performed to determine the prognostic potential of nuclear or cytoplasmic hnRNP K expression for HNSCCs in comparison with known clinical and pathologic parameters—histologic grade, tumor stage and nodal status (Table III). Cytoplasmic hnRNP K expression emerged as the most significant independent prognostic marker for HNSCCs ($p = 0.014$, HR = 6.1, 95% CI = 1.2–3.7). These findings clearly demonstrate the potential of cytoplasmic hnRNP K as a marker for predicting poor prognosis of HNSCCs.

RT-PCR, confocal laser scan microscopy and immunoblotting

The expression of hnRNP K in oral lesions was further validated by RT-PCR analyses and immunoblotting in the same tissue samples as used for immunohistochemical analysis. RT-PCR analysis demonstrated increased levels of hnRNP K transcripts in the head-

and-neck cancer cells (SCC4, HSC2, Tu167 and MDA1986) and tissue specimens of leukoplakias and HNSCCs in comparison with normal tissues (Fig. 4a). CLSM analysis showed intense nuclear and moderate cytoplasmic expression of hnRNP K protein in oral cancer cells, SCC4, as shown in Fig. 4b. Immunoblot analysis showed a single intense band of 64 kDa, confirming the increased expression of hnRNP K in SCC4 cells used as positive control, oral leukoplakias and HNSCCs, compared with the normal tissues (Fig. 4c), thus, supporting our findings of immunohistochemistry.

Discussion

The significant features of our study are its prospective nature, the large number of patients in this type of disease setting and the length of follow-up of HNSCC patients. hnRNP K expression in early oral lesions is a very important, hitherto unknown finding.

TABLE III – MULTIVARIATE ANALYSIS OF OVERALL SURVIVAL FOR CLINICOPATHOLOGIC PARAMETERS AND hnRNP K EXPRESSION

S. No.	Clinicopathologic parameter	p
1	Histopathologic grade	0.811
2	Tumor stage	0.100
3	Nodal status	0.142
4	hnRNP K (nuclear)	0.345
5	hnRNP K (cytoplasmic)	0.014

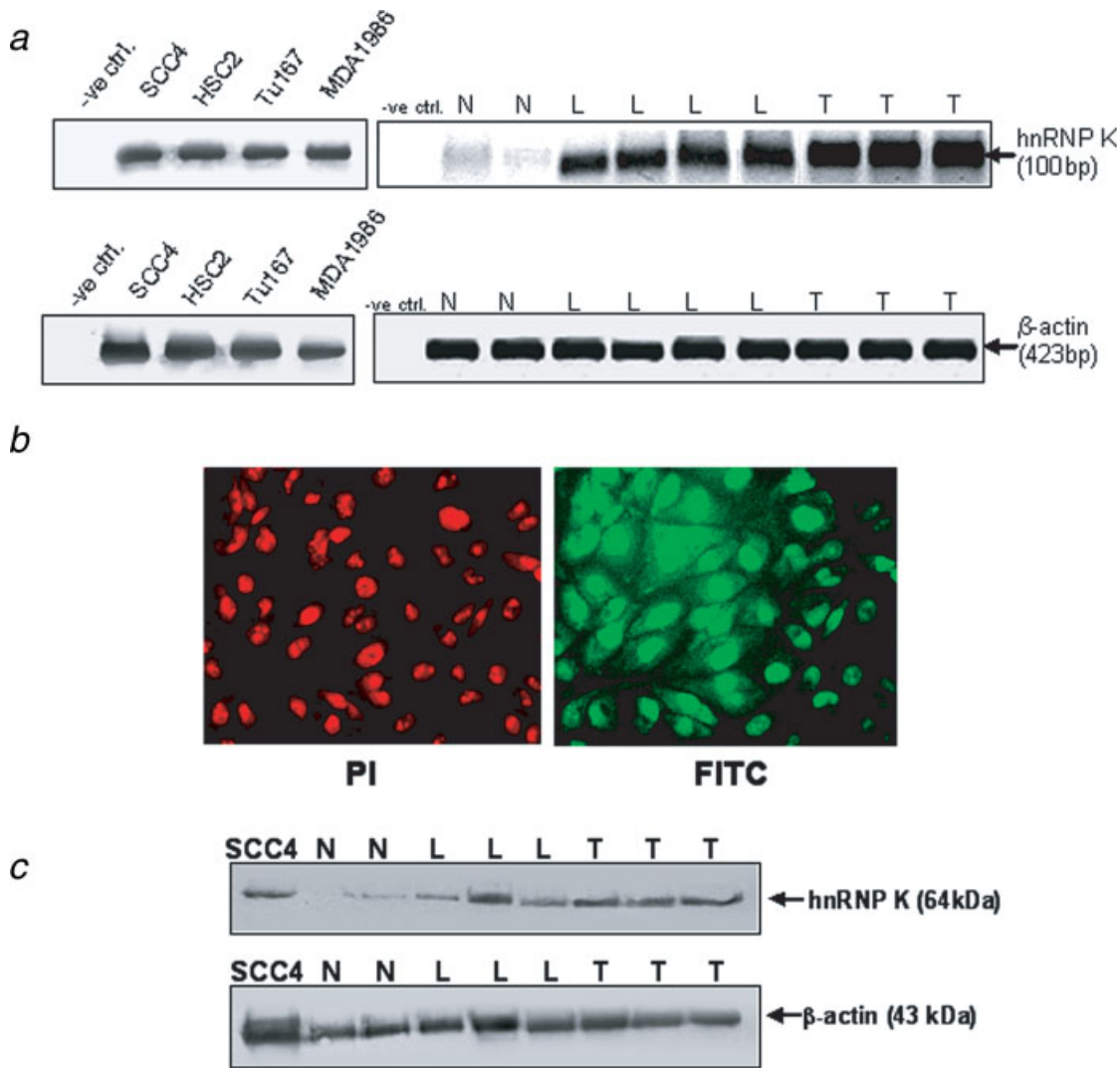


FIGURE 4 – Validation of hnRNP K expression. (a) RT-PCR analysis of hnRNP K in normal mucosa, leukoplakia and HNSCC tissues. Panel shows increased levels of hnRNP K transcripts in leukoplakia (L) and HNSCCs (T) compared with the nonmalignant head and neck tissues that showed basal levels (N) of hnRNP K transcripts. β-actin used as a control to normalize the quantity of RNA used for each RT-PCR reaction is shown in the lower panel. **(b)** Immunofluorescence of hnRNP K protein in head and neck cancer cells, SCC4. Cells were fixed and immunolabeled with anti-hnRNP K antibody followed by FITC-labeled secondary antibody (green fluorescence) and counterstained with propidium iodide (red fluorescence). **(a)** Nuclei showing red fluorescence of propidium iodide. **(b)** Green fluorescence in nucleus and cytoplasm of SCC4 cells showing subcellular localization of hnRNP K protein. **(a, b)** original magnification ×200. **(c)** Western blot analysis of hnRNP K in normal mucosa, leukoplakia and HNSCC tissues and SCC4 cells. Equal amount of protein lysates from these tissues were electrophoresed on 12% SDS-PAGE and transferred to PVDF membrane. The membrane was incubated with respective primary antibodies and secondary antibodies as described in the Methods section and the signal detected by enhanced chemiluminescence method. Panel shows increased expression of hnRNP K in leukoplakia (L) and HNSCCs (T) compared with paired nonmalignant head and neck tissues (N). Whole cell lysate prepared from SCC4 cells were used a positive control. β-actin was used as control for equal loading of protein in SDS-PAGE (lower panel).

This result provides the clinical evidence in support of hnRNP Ks proposed role as a transformation-related protein. To our knowledge, this is the first investigation demonstrating the clinical application of a candidate biomarker discovered using MS-based tissue proteomics that can identify oral leukoplakic lesions in early stages, before onset of dysplasia. The salient findings of our study are (i) nuclear hnRNP K expression increases from oral normal tissues to leukoplakia and frank malignancy and may serve as a diagnostic marker for HNSCCs; (ii) cytoplasmic accumulation of hnRNP K is increased significantly from leukoplakia to cancer; and (iii) cytoplasmic accumulation of hnRNP K is associated with poor prognosis of HNSCCs and can serve as a predictor of disease recurrence in HNSCC patients treated for the primary cancer.

Expression profiling of different cancer types and mechanistic studies have strongly implicated hnRNP K as a key player in human cancers.^{11,14–20,23,24} To our knowledge, this study is the first report demonstrating increased expression of hnRNP K in oral leukoplakia by immunohistochemistry. The significantly increased nuclear expression of hnRNP K in leukoplakic lesions with no dysplasia points to this alteration being an early event in the development of premalignant lesions and is in accord with its role as a transcriptional regulator of growth, promoting the *myc* and *src* genes, as well as cell proliferation.^{12,32–37}

The major challenge in oral tumorigenesis is the identification of proteins that may serve as markers to predict high-risk leukoplakia for early intervention. The average cumulative risk of leukoplakia to undergo malignant transformation in different studies amounted to 3–8.1%,³⁸ whereas an average annual transformation rate of 1% has been reported in a meta-analysis study.³⁹ In this context, the aberrant cytoplasmic accumulation of hnRNP K protein in a small subset of leukoplakias (26/199, 13% cases) and larger proportion of HNSCCs (38%) is noteworthy. Most studies on leukoplakia focus on dysplastic lesions, although knowledge of molecular alterations in leukoplakic lesions with no dysplasia is meager. As per the existing literature, the malignant transformation potential is often linked to the severity of dysplasia; in comparison, the leukoplakic lesions with no dysplasia have received less attention, primarily because these lesions often undergo spontaneous regression. However, there is urgent need to identify molecular markers to predict the risk of malignant transformation of lesions that do not regress. In this context, our study assumes importance, because it shows aberrant hnRNP K expression in leukoplakic lesions with no dysplasia and sustained expression in leukoplakic lesions with dysplasia and HNSCCs. Long-term follow-up of these leukoplakia patients is needed to establish the link, if any, between cytoplasmic hnRNP K and risk of cancer development. It is noteworthy that studies on molecular analysis of leukoplakic lesions with no dysplasia are very limited, because these patients often do not seek medical attention as their lesions are small and do not pose any overt clinical problem to the patients. Nevertheless, it is extremely important to target this patient population for risk assessment and early intervention for cancer prevention in high-risk cases. Further, the cytoplasmic expression of hnRNP K protein observed in epithelial cells of a subset of leukoplakic lesions with no dysplasia and dysplastic lesions points to a potential role in development and progression during early stages of oral tumorigenesis, whereas the overexpression in HNSCCs and association with poor prognosis suggests a sustained involvement in frank malignancy as well.

Importantly, Kaplan–Meier survival analysis revealed an association of cytoplasmic hnRNP K expression with poor prognosis of HNSCC; it also emerged as an independent prognostic marker in

multivariate analysis, in comparison with the known clinical and pathologic factors for HNSCCs including clinical stage, histologic grade and lymph nodal positivity. Further, analysis of the predictive potential of hnRNP K revealed its utility as a marker to identify aggressive HNSCCs, supporting the association observed by Kaplan–Meier analysis and logistic regression analysis.

Interestingly, aberrant cytoplasmic hnRNP K protein expression has also been observed in colorectal cancers.¹⁸ Significantly, nasopharyngeal carcinoma patients showing cytoplasmic hnRNP K were reported to have significantly reduced distant metastasis-free survival.¹⁷ The cytoplasmic hnRNP K expression may be attributed to the presence of an N-terminal bipartite nuclear localization signal and an hnRNP K-specific nuclear shuttling signal that confers the capacity for bidirectional transport across the nuclear envelope.³⁴ Recently, the K nuclear shuttling (KNS) domain, a well-known signal for nuclear import and export, has also been shown to be responsible for the transactivation activity of hnRNP K protein.⁴⁰ The cytoplasmic accumulation of hnRNP K is controlled by extracellular signal-regulated kinase-dependent serine phosphorylation (Ser²⁸⁴ and Ser³⁵³).^{41,42} In the cytoplasm, hnRNP K functions as a translational regulator of specific mRNAs, including those of *c-myc*, renin, the human papillomavirus type 16 L2 capsid protein, and reticulocyte-15-lipoxygenase (r15-LOX).^{12,43–45} HPV 16 and 18 have been associated with a large proportion of HNSCCs, especially among nonconsumers of tobacco, although the molecular mechanisms underlying the development of HPV-associated HNSCCs are under intense investigation. Recent proteomic analysis of HPV-positive and -negative OSCCs have revealed differences in protein expression patterns; whether hnRNP K plays different roles in these tumor subtypes remains to be investigated.⁴⁶ In the cytoplasm, hnRNP K functions as a specific activator of c-Src and is a substrate of this tyrosine kinase. c-Src-dependent phosphorylation modulates the r15-LOX mRNA-binding activity of hnRNP K and its function in the control of mRNA translation during erythroid cell maturation.^{31,32,45} Taken together with the diverse influence of hnRNP K on gene expression and mechanisms regulating hnRNP K subcellular localization, we speculate that gene dysregulation resulting from cytoplasmic accumulation of hnRNP K may play an important role in tumorigenesis.

In summary, hnRNP K was shown to be expressed in oral lesions in early stages, before onset of dysplasia and in frank tumors. Further, its subcellular localization, predominantly nuclear in leukoplakia, but increased cytoplasmic expression in tumor cells, suggests that nuclear-cytoplasmic translocation may have an important role in malignant transformation of oral cancer cells that merits investigation in future studies. The most important finding is that cytoplasmic hnRNP K is a predictor of poor prognosis in HNSCCs. Large-scale longitudinal studies are warranted to evaluate hnRNP Ks potential as an indicator of progression risk in leukoplakia and role in development and progression during early stages of head-and-neck/oral tumorigenesis.

Acknowledgements

R.R. gratefully acknowledges support from the Ontario Institute for Cancer Research (OICR), Joseph and Mildred Sonshine Centre for Head and Neck Diseases and Temmy Latner/Dynacare Family Foundation, Canada. We thank Applied Biosystems for reagent support. K.W.M.S. acknowledges support from the Canadian Institutes of Health Research (CIHR), Ontario Research and Development Challenge Fund and Applied Biosystems/MDS Analytical Technologies.

References

1. Jemal A, Siegel R, Ward E, Hao Y, Xu J, Murray T, Thun MJ. Cancer statistics, 2008. *CA Cancer J Clin* 2008;58:71–96.
2. Hunter KD, Parkinson EK, Harrison PR. Profiling early head and neck cancer. *Nat Rev Cancer* 2005;5:127–35.
3. Warnakulasuriya KA, Ralhan R. Clinical, pathological, cellular and molecular lesions caused by oral smokeless tobacco. *J Oral Pathol Med* 2007;36:63–77.
4. Warnakulasuriya S, Johnson NW, van der Waal I. Nomenclature and classification of potentially malignant disorders of the oral mucosa. *J Oral Pathol Med* 2007;36:575–80.
5. Warnakulasuriya S, Reibel J, Bouquot J, Dabelsteen E. Oral epithelial dysplasia classification systems: predictive value, utility, weaknesses and scope for improvement. *J Oral Pathol Med* 2008;37:127–33.

6. Brennan M, Migliorati CA, Lockhart PB, Wray D, Al-Hashimi I, Axéll T, Bruce AJ, Carpenter W, Eisenberg E, Epstein JB, Holmstrup P, Jontell M, et al. Management of oral epithelial dysplasia: a review. *Oral Surg Oral Med Oral Pathol Oral Radiol Endod* 2007;103:S19e1–12.
7. Valverde R, Edwards L, Regan L. Structure and function of KH domains. *FEBS J* 2008;275:2712–26.
8. Michelotti EF, Michelotti GA, Aronsohn AI, Levens D. Heterogeneous nuclear ribonucleoprotein K is a transcription factor. *Mol Cell Biol* 1996;16:2350–60.
9. Bomsztyk K, Denisenko O, Ostrowski J. hnRNP K: one protein multiple processes. *Bioessays* 2004;26:629–38.
10. Lynch W, Chen L, Ravitz MJ, Mehtani S, Korenblat K, Pazin MJ, Schmidt EV. hnRNP K binds a core polypyrimidine element in the eukaryotic translation initiation factor 4E (eIF4E) promoter, and its regulation of eIF4E contributes to neoplastic transformation. *Mol Cell Biol* 2005;25:6436–53.
11. Carpenter B, MacKay C, Alnabulsi A, MacKay M, Telfer C, Melvin WT, Murray GI. The roles of heterogeneous nuclear ribonucleoproteins in tumour development and progression. *Biochim Biophys Acta* 2006;1765:85–100.
12. Evans JR, Mitchell SA, Spriggs KA, Ostrowski J, Bomsztyk K, Ostarek D, Willis AE. Members of the poly (rC) binding protein family stimulate the activity of the c-myc internal ribosome entry segment *in vitro* and *in vivo*. *Oncogene* 2003;22:8012–20.
13. Moumen A, Masterson P, O'Connor MJ, Jackson SP. hnRNP K: an HDM2 target and transcriptional coactivator of p53 in response to DNA damage. *Cell* 2005;123:1065–78.
14. Ostarek-Lederer A, Ostarek DH. Control of mRNA translation and stability in haematopoietic cells: the function of hnRNPs K and E1/E2. *Biol Cell* 2004;96:407–11.
15. Hatakeyama H, Kondo T, Fujii K, Nakanishi Y, Kato H, Fukuda S, Hirohashi S. Protein clusters associated with carcinogenesis, histological differentiation and nodal metastasis in esophageal cancer. *Proteomics* 2006;6:6300–16.
16. Pino I, Pío R, Toledo G, Zabalegui N, Vicent S, Rey N, Lozano MD, Torre W, García-Foncillas J, Montuenga LM. Altered patterns of expression of members of the heterogeneous nuclear ribonucleoprotein (hnRNP) family in lung cancer. *Lung Cancer* 2003;41:131–43.
17. Sun Y, Yi H, Zhang PF, Li MY, Li C, Li F, Peng F, Feng XP, Yang YX, Yang F, Xiao ZQ, Chen ZC. Identification of differential proteins in nasopharyngeal carcinoma cells with p53 silencing by proteome analysis. *FEBS Lett* 2007;581:131–9.
18. Carpenter B, McKay M, Dundas SR, Lawrie LC, Telfer C, Murray G. Heterogeneous nuclear ribonucleoprotein K is over expressed, aberrantly localized and is associated with poor prognosis in colorectal cancer. *Br J Cancer* 2006;95:921–7.
19. de Hoog CL, Foster LJ, Mann M. RNA and RNA binding proteins participate in early stages of cell spreading through spreading initiation centers. *Cell* 2004;117:649–62.
20. Inoue A, Sawata SY, Taira K, Wadhwa R. Loss-of-function screening by randomized intracellular antibodies: identification of hnRNP-K as a potential target for metastasis. *Proc Natl Acad Sci USA* 2007;104:8983–8.
21. Mandal M, Vadlamudi R, Nguyen D, Wang RA, Costa L, Bagheri-Yarmand R, Mendelsohn J, Kumar R. Growth factors regulate heterogeneous nuclear ribonucleoprotein K expression and function. *J Biol Chem* 2001;276:9699–704.
22. Aman P, Panagopoulos I, Lassen C, Fioretos T, Mencinger M, Toreson H, Höglund M, Forster A, Rabbitts TH, Ron D, Mandahl N, Mitelman F. Expression patterns of the human sarcoma-associated genes FUS and EWS and the genomic structure of FUS. *Genomics* 1996;37:1–8.
23. Roychoudhury P, Chaudhuri K. Evidence for heterogeneous nuclear ribonucleoprotein K overexpression in oral squamous cell carcinoma. *Br J Cancer* 2007;97:574–5.
24. Ralhan R, DeSouza LV, Matta A, Chandra Tripathi S, Ghanny S, Dattagupta S, Thakar A, Chauhan SS, Siu KW. iTRAQ-multidimensional liquid chromatography and tandem mass spectrometry based identification of potential biomarkers of oral epithelial dysplasia and novel networks between inflammation and premalignancy. *J Proteome Res* 2009;8:300–9.
25. DeSouza LV, Taylor AM, Li W, Minkoff MS, Romaschin AD, Colgan TJ, Siu KW. Multiple reaction monitoring of mTRAQ-labeled peptides enables absolute quantification of endogenous levels of a potential cancer marker in cancerous and normal endometrial tissues. *J Proteome Res* 2008;7:3525–34.
26. Ralhan R, DeSouza LV, Matta A, Chandra Tripathi S, Ghanny S, Datta Gupta S, Bahadur S, Siu KW. Discovery and verification of head-and-neck cancer biomarkers by differential protein expression analysis using iTRAQ labeling, multidimensional liquid chromatography, and tandem mass spectrometry. *Mol Cell Proteomics* 2008;7:162–73.
27. Matta A, DeSouza LV, Shukla NK, Gupta SD, Ralhan R, Siu KW. Prognostic significance of head-and-neck cancer biomarkers previously discovered and identified using iTRAQ-labeling and multidimensional liquid chromatography-tandem mass spectrometry. *J Proteome Res* 2008;7:2078–87.
28. Moskowitz CS, Pepe MS. Quantifying and comparing the accuracy of binary biomarkers when predicting a failure time outcome. *Statist Med* 2004;23:1555–1570.
29. Pepe MS. The statistical evaluation of medical tests for classification and prediction. Oxford University Press, Oxford; 2003.
30. Matta A, Bahadur S, Duggal R, Gupta SD, Ralhan R. Over-expression of 14–3-3zeta is an early event in oral cancer. *BMC Cancer* 2007;7:169.
31. Arora S, Matta A, Shukla NK, Deo SV, Ralhan R. Identification of differentially expressed genes in oral squamous cell carcinoma. *Mol Carcinog* 2005;42:97–108.
32. Adolph D, Flach N, Mueller K, Ostarek DH, Ostarek-Lederer A. Deciphering the cross talk between hnRNP K and c-Src: the c-Src activation domain in hnRNP K is distinct from a second interaction site. *Mol Cell Biol* 2007;27:1758–70.
33. Naarmann IS, Harnisch C, Flach N, Kremmer E, Kühn H, Ostarek DH, Ostarek-Lederer A. mRNA silencing in human erythroid cell maturation: hnRNP K controls the expression of its regulator c-Src. *J Biol Chem* 2008;283:18461–72.
34. Ostrowski J, Bomsztyk K. Nuclear shift of hnRNP K protein in neoplasms and other states of enhanced cell proliferation. *Br J Cancer* 2003;89:1493–501.
35. Bomsztyk K, Denisenko O, Ostrowski J. hnRNP K: one protein multiple processes. *Bioessays* 2004;26:629–38.
36. He Y, Brown MA, Rothnagel JA, Saunders NA, Smith R. Roles of heterogeneous nuclear ribonucleoproteins A and B in cell proliferation. *J Cell Sci* 2005;118:3173–83.
37. Michael WM, Eder PS, Dreyfuss G. The K nuclear shuttling domain: a novel signal for nuclear import and nuclear export in the hnRNP K protein. *EMBO J* 1997;16:3587–98.
38. Scully C, Porter S. ABC of oral health. Oral cancer. *BMJ* 2000;321:97–100.
39. Hunter KD, Parkinson EK, Harrison PR. Profiling early head and neck cancer. *Nat Rev Cancer* 2005;5:127–35.
40. Chan JY, Huang SM, Liu ST, Huang CH. The transactivation domain of heterogeneous nuclear ribonucleoprotein K overlaps its nuclear shuttling domain. *Int J Biochem Cell Biol* 2008;40:2078–89.
41. Habelhah H, Shah K, Huang L, Ostarek-Lederer A, Burlingame AL, Shokat KM, Hentze MW, Ronai Z. ERK phosphorylation drives cytoplasmic accumulation of hnRNP-K and inhibition of mRNA translation. *Nat Cell Biol* 2001;3:325–30.
42. Wolf D, Witte V, Clark P, Blume K, Lichtenheld MG, Baur AS. HIV Nef enhances Tat-mediated viral transcription through a hnRNP-K-nucleated signaling complex. *Cell Host Microbe* 2008;4:398–408.
43. Skalweit A, Doller A, Huth A, Kähne T, Persson PB, Thiele BJ. Post-transcriptional control of renin synthesis: identification of proteins interacting with renin mRNA 3'-untranslated region. *Circ Res* 2003;92:419–27.
44. Collier B, Goobar-Larsson L, Sokolowski M, Schwartz S. Translational inhibition *in vitro* of human papillomavirus type 16 L2 mRNA mediated through interaction with heterogeneous ribonucleoprotein K and poly(rC)-binding proteins 1 and 2. *J Biol Chem* 1998;273:22648–56.
45. Reimann I, Huth A, Thiele H, Thiele BJ. Suppression of 15-lipoxygenase synthesis by hnRNP E1 is dependent on repetitive nature of LOX mRNA 3'-UTR control element DICE. *J Mol Biol* 2002;315:965–74.
46. Lo WY, Lai CC, Hua CH, Tsai MH, Huang SY, Tsai CH, Tsai FJ. S100A8 is identified as a biomarker of HPV18-infected oral squamous cell carcinomas by suppression subtraction hybridization, clinical proteomics analysis, and immunohistochemistry staining. *J Proteome Res* 2007;6:2143–51.